

# **Non-ablative hyperthermic mesenchymal regeneration: A proposed mechanism of action based on the Viveve™ model**

Jeffrey A. Vos, Ryan H. Livengood, Morris Jessop and James E. Coad \*  
West Virginia University Pathology Laboratory for Translational Medicine  
Mailstop 9203, 1 Medical Center Drive, Morgantown, WV, USA 26506

## **ABSTRACT**

Novel non-ablative hyperthermic medical devices are currently being developed, in association with cryogen surface cooling, to rejuvenate tissues without collagen scarring. These devices have been designed to remodel skin, manage urinary stress incontinence, and more recently, treat vaginal laxity. In contrast to the thermal injury and reparative healing associated with higher energy ablation systems, these lower energy non-ablative systems are designed to subtly modify the collagen, stimulate the fibroblasts, and maintain a functional tissue architecture that subsequently promotes tissue rejuvenation and restoration. While these devices have primarily relied on clinical outcome questionnaires and satisfaction surveys to establish efficacy, a physiologic explanation for the induced tissue changes and tightening has not been well documented. Recent histology studies, using the Viveve ovine vaginal treatment model, have identified changes that propose both a mechanism of action and a tissue remodeling timeline for such non-ablative hyperthermic devices. The Viveve model results are consistent with subtle connective tissue changes leading to fibroblast stimulation and subsequent collagen replacement and augmentation. Unlike tissue ablation devices that cause thermal necrosis, these non-ablative devices renew the targeted tissue without dense collagenous scarring over a period of 3 or more months. The spectrum of histologic findings, as illustrated in the Viveve ovine vaginal model, further support the previously documented safety and efficacy profiles for low-dose non-ablative hyperthermic devices that rejuvenate and tighten submucosal tissues.

**Keywords:** Non-ablative hyperthermic medical technologies, low-dose radiofrequency thermal therapy, tissue remodeling, tissue rejuvenation, fibroblast activation, tissue healing, tissue tightening

## **1. INTRODUCTION**

While the clinical and histologic changes associated with high-dose ablative radiofrequency (RF) devices have been well documented, similar information is not widely available for the low-dose non-ablative RF therapies. The number of these low-dose RF applications is increasing in the fields of aesthetic medicine, gynecology and others. For example, low-dose RF energy is used to clinically tighten skin, and much of our current understanding derives its basis from this application.<sup>1-7</sup> A theme common to these devices is the carefully controlled application of “non-ablative” RF energy levels to subtly change collagen and promote tissue renewal. Therefore, achieving the desired clinical outcome requires delivering a thermal dose which is adequate to stimulate tissue rejuvenation yet insufficient to cause cellular necrosis with subsequent scarring. Since many clinical studies have largely relied on patient satisfaction surveys,<sup>5,8,9</sup> these treatment modalities have variably encountered some degree of skepticism in the medical community. Objective information on the histologic changes associated with low-energy/non-ablative RF treatments is thus needed to aid in our understanding and to substantiate the clinical outcomes.

A novel low-dose RF application is for the treatment of vaginal laxity. Laxity of the vaginal introitus can occur following vaginal childbirth. This is due to stretching and potential tissue damage associated with the infant’s passage through the birth canal. Subsequently, laxity may persist and lead to diminished or altered vaginal sensation, decreased sexual satisfaction and/or sexually-related personal distress. Depending on their severity, these items can result in minor inconveniences to significant reductions in a patient’s quality of life. Therefore, understanding the

\* jcoad@hsc.wvu.edu; phone: 304-685-6124

need to treat vaginal laxity using minimally invasive thermal techniques has generated increasing interest. Recent studies have shown promise for using non-ablative low-dose RF to restore vaginal connective tissues with the goal of tightening the introitus.<sup>8,10</sup> This paper documents the histologic findings for a series of ovine vaginal introitus biopsies obtained after treatment with the Viveve™ low-dose RF system (Viveve, Palo Alto, CA) that is under development for the treatment of vaginal laxity in women.

## 2. MATERIALS AND METHODS

### 2.1 Laboratory Processing

Ovine vaginal introitus biopsies were obtained for histologic evaluation following treatment with the Viveve™ low-dose radiofrequency system. Non-overlapping introitus biopsies were obtained from different ovine at 7, 30 and 90 days post-treatment. The introitus regions were treated with a spectrum of low to high energy doses. The formalin-fixed biopsies were oriented in tissue cassettes, routinely processed overnight and paraffin-embedded. Two 5-micron hematoxylin-eosin stained slides were prepared from each paraffin block. A Gomori trichrome stain was also prepared from each block to assess for increases in collagen. Using routine light microscopy, the slides were histologically evaluated. The pathologists were blinded to the applied treatment characteristics until the completion of the study.

### 2.2 Histologic Evaluation

Overall, the vaginal mucosa and submucosa were evaluated for signs of tissue injury, fibroblast activation and qualitative collagen changes. The mucosa was categorized as intact, eroded or ulcerated based on the following criteria: The mucosa was considered *intact* when the surface was covered by unremarkable stratified non-keratinized squamous epithelium; the mucosa was considered *eroded* when the surface epithelium was variably disrupted with surface fibrin and/or acute inflammation; and the mucosa was considered *ulcerated* when the epithelium was at least focally absent with disruption/loss of underlying submucosal tissue and associated acute inflammation.

The biopsies were assessed for the presence or absence of granulation tissue, consistent with subacute tissue repair and a sign of regional tissue injury. The biopsies were also evaluated for coagulative necrosis, consistent with thermal tissue necrosis. If present, these two findings were scored as focal or diffuse in nature.

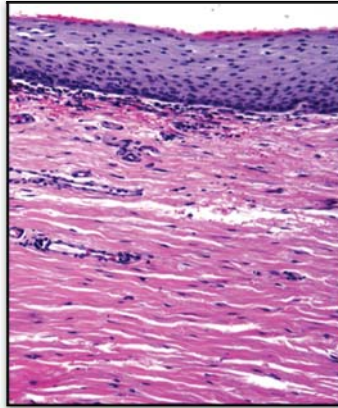
The submucosa was assessed for histologic signs of fibroblast activation. The fibroblasts were considered to be quiescent when they had condensed nuclear chromatin and scant cytoplasm. The fibroblasts were considered activated when they had reticular or open chromatin and increased cytoplasm. When present, the stimulated or activated fibroblasts were scored as focal or diffuse in nature. Based on their prominence and density in comparison to untreated control tissue, the stimulated fibroblasts were graded as being minimally, mildly, moderately or extensively activated. *Minimal* stimulation was defined as activated nuclear changes in some fibroblasts without increased numbers. *Mild* activation showed activated nuclear changes in most fibroblasts with a slight increase in numbers compared to the control tissue. *Moderate* activation was defined as the presence of activated changes in essentially all fibroblasts, focal clustering of nuclei, and increased numbers. *Extensive* activation involved virtually all fibroblasts with notable clustering of nuclei and increased numbers.

In addition to fibroblast activation, the submucosa was qualitatively assessed for the presence or absence of increased collagen. In biopsies where the collagen appeared increased compared to the normal control tissue, the following qualitative scoring system was used: *minimal* if the collagen appeared to have a slightly increased fiber density, intact fibrillary architecture and normal cellular density; *mild* if the collagen fibers appeared slightly courser or more compact (directionally aligning) without a decrease in regional cellularity; *moderate* if the collagen fibers appeared moderately courser or compact (directionally aligning) with mild regional hypocellularity; or *extensive* if the collagen fibers appeared densely compacted or hyalinized (hypertrophic scar-like) with associated regional hypocellularity.

### 3. RESULTS

#### 3.1 Control Tissue

To establish a histologic baseline for comparison, three ovine vaginal introitus control biopsies were evaluated. The control biopsies showed intact, relatively unremarkable, stratified non-keratinized squamous epithelium. These biopsies showed variable numbers of subepithelial lymphoid aggregates and non-specific chronic interface inflammation; however, features of stromal remodeling and thermal injury were lacking as expected (Figure 1).



**Figure 1.** Normal control vaginal mucosa: The stratified squamous epithelium is intact with minimal non-specific lymphocytic interface inflammation. The submucosa shows the typical fibrillary, basket weave-like collagen architecture with no discernible collagen increase. The fibroblasts are uniformly scattered with hyperchromatic condensed nuclear chromatin, indicative of an unstimulated state.

#### 3.2 Histologic Features of Low-Energy Ablative versus Non-Ablative Boundary

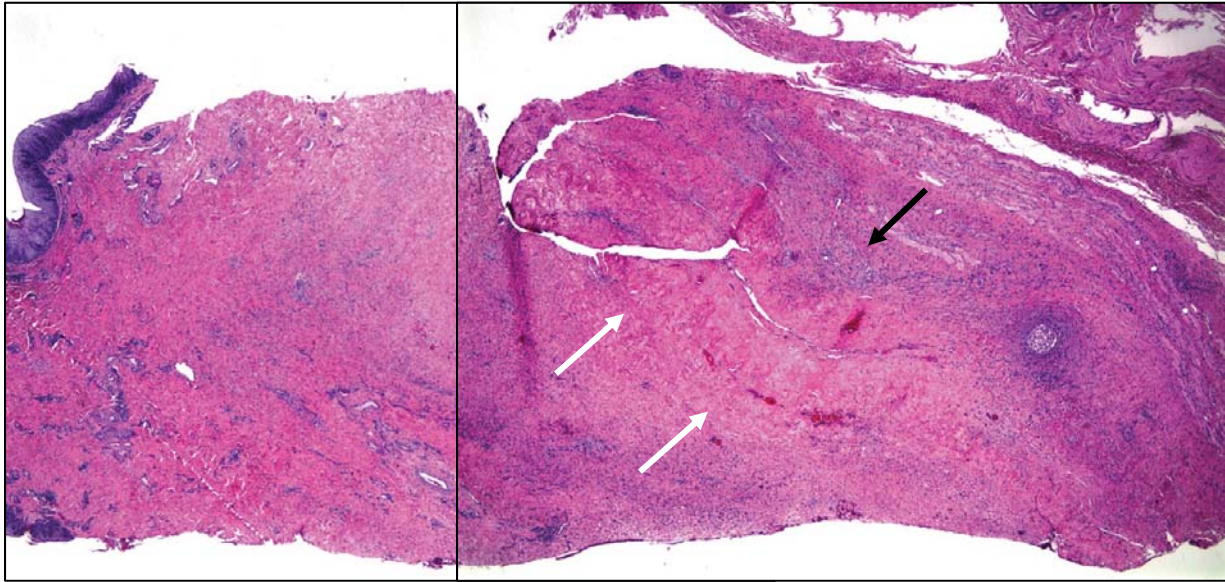
To verify the ovine vaginal model's ability to detect the effects of under treatment (control-like histology) and over treatment (thermal ablative changes), the vaginal mucosa was subjected to a spectrum of RF thermal doses. Under-treated biopsies lacked fibroblast activation and appeared similar to the control biopsies (Figure 1). The over-treated biopsies (Figure 2) showed dense central collagen deposition consistent with scar formation (Figure 3A). The surrounding tissue showed increased vascularity and inflammatory cells characteristic of granulation tissue (Figure 3B). Adjacent to the granulation tissue was an outer ring with extensive fibroblast activation. As expected, the over-treated biopsies demonstrated regional thermal tissue injury with a subsequent fibroproliferative wound-healing response, consistent with a low-energy thermal tissue ablation. As these latter changes lead to tissue scarring, they should not normally be identified in low-dose non-ablative RF treatments.

#### 3.3 Non-Ablative Treatment: Fibroblast Activation

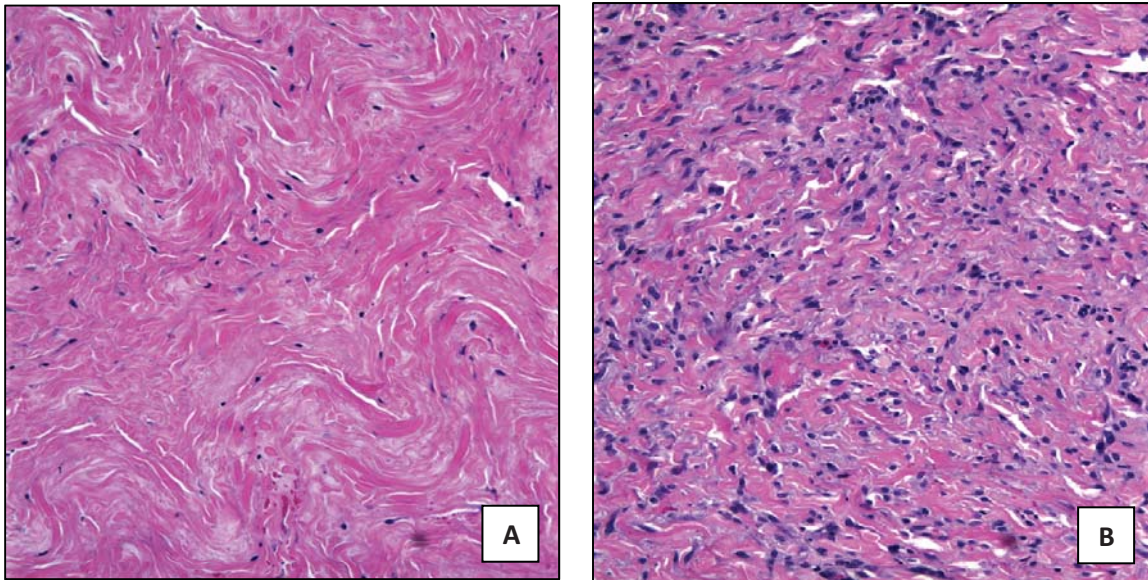
Following optimized low-dose non-ablative RF treatments, variable fibroblast activation was observed within the submucosa that correlated with the RF generated thermal history (time and temperature). The fibroblasts demonstrated open reticular nuclear chromatin (loss of hyperchromasia) and a mild increase in cell size. These fibroblasts variably showed more distinct plentiful cytoplasm and increased numbers. While more evenly dispersed when quiescent or mildly activated, focal fibroblast clustering was identified with more moderate to extensive activation (Figure 4). These biopsies lacked mucosal damage, tissue necrosis, granulation tissue and hypertrophic scar-like collagen deposition (histologic over treatment features).

#### 3.4 Non-Ablative Treatment: Submucosal Collagen Changes

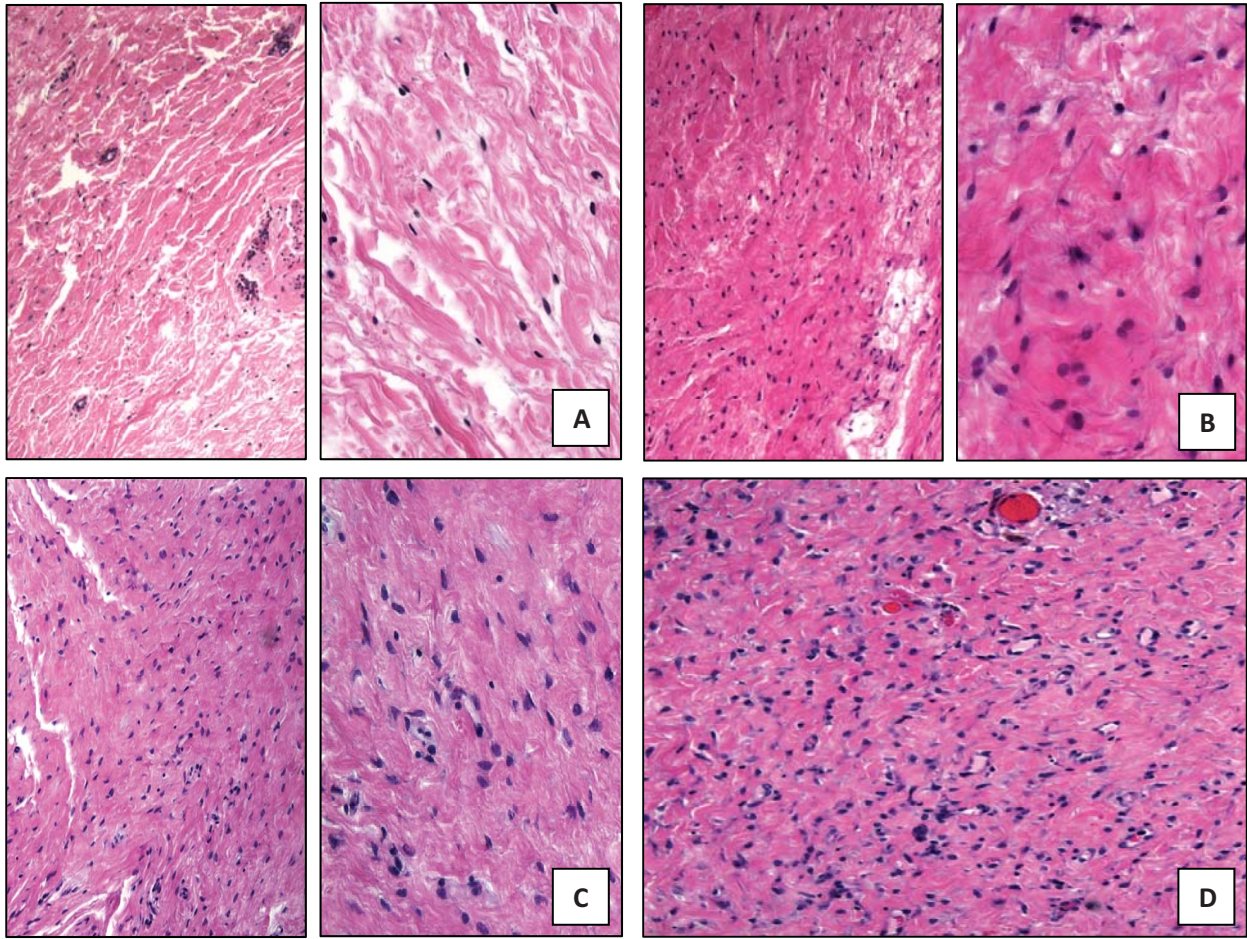
The vaginal biopsies were evaluated for potential submucosal collagen increases compared to the control biopsies. Hematoxylin and eosin as well as Gomori's trichrome stained sections were reviewed for collagen changes. Diffuse mild with or without focal moderate increases in collagen were observed beginning around Day 30 post-treatment. In general, these biopsies did not have significantly increased collagen levels that would suggest a loss of tissue compliance or hypertrophic scar formation.



**Figure 2.** Over-treated vaginal mucosa (hematoxylin and eosin, 20x) showing the histologic features of a low-energy RF ablation. The submucosa contains centrally dense compact collagen with directionally aligned fibers and a marked decrease in cellularity (white arrows; Figure 3A). An adjacent ring of granulation tissue (black arrow; Figure 3B) and fibroblast activation is present. These features are characteristic of hypertrophic scarring as a result of thermal tissue necrosis with subsequent wound healing.



**Figure 3.** Histology of over-treated vaginal mucosa: **A.** Dense variably hyalinized collagen with decreased cellularity characteristic of hypertrophic scarring (Fig. 2, white arrows). **B.** Outer ring of wound healing (Fig. 2, black arrow) showing increased microvasculature, inflammatory cells and activated fibroblasts, consistent with resolving granulation tissue. These histologic features illustrate the spectrum of reparative changes associated with wound healing following thermal injury.



**Figure 4.** Fibroblast activation in response to low-dose non-ablative RF treatment: **A.** Submucosal control biopsy illustrating a baseline number of unstimulated fibroblasts with hyperchromatic nuclei. **B.** Mild fibroblast activation showing increased cell numbers with variably open chromatin. **C.** Mild to focally moderate fibroblast activation characterized by increased cell numbers with focal nuclear clustering. **D.** Extensive fibroblast activation taken from an “over-treated” biopsy for comparison. There is a marked increase in fibroblast number with cellular clustering and activated-appearing nuclei.

### 3.5 Non-Ablative Treatment: Timeline of Stromal Remodeling

Following optimal low-energy RF treatment, increased fibroblast activation was identified over a period of time. Day 7 post-treatment biopsies often showed quiescent to focally mild fibroblast activation, similar to that seen in the control biopsies. Beginning around Day 30 post-treatment, fibroblast activation and collagen changes above control levels were identified. The fibroblast activation and collagen increases generally persisted in the Day 90 post-treatment biopsies.

## 4. CONCLUSIONS

### 4.1 Ablative versus Non-Ablative Hyperthermic Treatment

A variety of minimally invasive thermal devices employ suprphysiologic temperatures to ablate or thermally

necrose the targeted tissues. These higher-dose thermal ablations result in primary thermal tissue injury that, depending on tissue type and thermal history achieved, results in cell death or vaporization. Clinical applications for these high-dose ablative treatments include kidney and liver tumors, endometrial ablation for menorrhagia, prostate ablation for benign hypertrophy and multiple others. Using lower thermal doses, ablative therapies can be used to intentionally injure tissue to stimulate a wound healing response with subsequent tissue regeneration or scar formation. This latter form of ablative therapy has found applications in correcting cardiac electroconduction anomalies and other medical conditions that benefit from regional tissue regeneration and/or fibrosis.

Other hyperthermic devices use lower non-ablative thermal histories to subtly denature collagen and subsequently stimulate tissue rejuvenation and restoration. As implied by the category's name, the thermal histories delivered by these devices are insufficient to result in thermal cellular necrosis. In contrast to the low-dose ablative therapies, cellular viability and a functional tissue framework are preserved with the non-ablative applications. Within the treated region, fibroblast activation, connective tissue rejuvenation and tissue tightening are the hallmarks of low-dose non-ablative therapies. In this setting, the tissue changes do not incite classical reparative wound healing with inflammation, angiogenesis and scar formation.

#### **4.2 Radiofrequency Mechanism of Action**

A variety of methodologies are available for tissue heating, which generally have similar effects based on the thermal histories they generate. Low-dose non-ablative RF devices have gained popularity for a number of medical applications, especially for dermal remodeling. One reason for this is that RF energy is not absorbed by melanin pigment like some light-based systems.<sup>7</sup> Typical radiofrequency systems are comprised of an RF generator, a treatment electrode and a cooling module. When activated, the electrode builds up a charge that creates an electrical field in the underlying tissue. As the energy is delivered, charged molecules within the tissue move and produce heat. This heat, in turn, modifies the tissue and initiates the desired treatment effects.<sup>11</sup> RF systems can be finely tuned to achieve desired thermal histories with a high degree of reproducibility, making them well-suited for precision non-ablative therapies.

#### **4.3 Radiofrequency Treatment Variables**

Following RF treatment, the remodeling changes that ensue are dependent upon the tissue itself and a number of variables related to the RF system.<sup>7</sup> The tissue's homogeneity and collagen fiber arrangement affect both the tissue's inherent resistance as well as the treatment's tightening effects. For example, tendinous tissue is composed of dense highly aligned collagen bundles, thus thermal treatment results in linear contraction and uniform collagen denaturation.<sup>12</sup> The RF treatment time and degree of surface cooling will also affect the extent of collagen matrix changes. Therefore, the overall treatment effect is both time and temperature dependent (i.e. thermal history). By modifying the thermal history, the RF system can be optimized for non-ablative outcomes. Surface cooling, with either water or cryogen spray, has the effect of producing a reverse heat gradient in which deeper tissues are heated and the surface skin or mucosa theoretically remains untreated. As a result, this model protects the mucosa from hyperthermic damage.

#### **4.4 Non-Ablative Radiofrequency Tissue Remodeling: Current Applications**

While many variables are involved in RF applications, the temperature generated and treatment time are the most important factors in determining tissue changes and clinical outcomes. At higher energy levels, extensive protein denaturation and cell death occur. These so-called "macroscopic" RF treatments have clinical utility when volumetrically ablating or necrosing tissue with subsequent reparative healing and scar formation. At lower levels, RF energy can be used to rejuvenate tissues at a "microscopic" level without associated cellular necrosis. These RF treatments subtly change the collagen and activate fibroblasts, which remodel the tissue without classical wound healing and scarring.<sup>13</sup>

A common objective of low-dose non-ablative RF treatments is shrinkage and tightening of the tissue's extracellular matrix to reduce tissue compliance without scar or stricture formation. These RF applications appear to be best suited for surface or luminal organs, as illustrated by its use in the treatment of stress urinary incontinence.<sup>14</sup> Since its introduction in 2002 and FDA approval in 2005, several longer-term studies have demonstrated safety and

efficacy using this procedure for treating urinary incontinence in women who cannot tolerate or do not desire surgical intervention.<sup>9,13-15</sup>

#### **4.5 Non-Ablative Radiofrequency Treatment of Vaginal Laxity: The Viveve Model**

The use of low-energy non-ablative RF to treat vaginal laxity follows a similar paradigm by stimulating mesenchymal restoration to tighten the tissue while avoiding cellular necrosis, neurovascular damage and reparative mechanisms leading to scar formation. Using the Viveve sheep model, the evolving histologic changes associated with non-ablative RF treatments have been better defined, support the efficacy and safety of this technique, and correlate with recent clinical observations.<sup>8</sup> Based on the histology, subtle collagen changes lead to fibroblast stimulation without disruption of the tissue framework or cell death. During the remodeling phase, it is hypothesized that structural collagen fiber modification (i.e., cross-linking, increased fiber size), old collagen replacement, and/or new extracellular matrix production result in the tissue's restoration.<sup>7,16</sup> Importantly, this process lacks cell death and reparative mechanisms which result in scar formation.

The histology would indicate that submucosal restoration begins in earnest approximately one month after treatment and continues for three or more months. This time course has potential clinical implications, as patients treated with low-energy non-ablative RF applications may not experience significant clinical improvement until one or more months following the procedure. Taking this into account, future studies should obtain longer-term follow-up to fully understand the rejuvenation/restoration process. As applications for low-energy non-ablative treatments continue to expand, future studies are needed to further delineate the underlying pathophysiology of the remodeling changes, improve therapeutic efficacy, and establish retreatment guidelines.

### **ACKNOWLEDGEMENTS**

The authors thank Viveve, Inc. (Palo Alto, CA) for funding this project and providing the histologic samples photographed in this manuscript.

### **REFERENCES**

- [1] Hantash, B.M, Ubeid, A.A., Chang, H., Kafi, R., and Renton, B., "Bipolar fractional radiofrequency treatment induces ne elastogenesis and neocollagenesis," *Lasers Surg Med* 41, 1-9 (2009).
- [2] Elsaie, M.L., "Cutaneous remodeling and photorejuvenation using radiofrequency devices," *Indian J Dermatol* 54(3), 201-205 (2009).
- [3] Hodgkinson, D.J., "Clinical applications of radiofrequency: nonsurgical skin tightening (thermage)," *Clin Plast Surg* 36(2), 261-268, viii (2009).
- [4] Alster, T.S. and Lupton, J.R., "Non-ablative cutaneous remodeling using radiofrequency devices," *Clinic Dermatol* 25, 487-491 (2007).
- [5] Dover, J.S., Zelickson, B., and 14-physician multispecialty consensus panel, "Results of a survey of 5,700 patient monopolar radiofrequency facial skin tightening treatments: assessment of a low-energy multiple-pass technique leading to a clinical end point algorithm," *Dermatol Surg* 33(8), 900-907 (2007).
- [6] Weiss, R.A., Weiss, M.A., Munavalli, G., and Beasley, K.L., "Monopolar radiofrequency facial tightening: a retrospective analysis of efficacy and safety in over 600 treatments," *J Drugs Dermatol* 5(8), 707-712 (2006).
- [7] Zelickson, B.D., Kist, D., Berstein, E., Brown, D.B., Ksenzenko, S., Burns, J., Kilmer, S., Mehregan, D., and Pope, K., "Histological and ultrastructural evaluation of the effects of a radiofrequency-based non-ablative dermal remodeling device," *Arch Dermatol* 140, 204-9 (2004).

- [8] Millheiser, L.S., Pauls, R.N., Herbst, S.J., and Chen, B.H., "Radiofrequency treatment of vaginal laxity after vaginal delivery: nonsurgical vaginal tightening," *J Sex Med* 7(9), 3088-3095 (2010).
- [9] Elser, D.M., Mitchell, G.K., Miklos, J.R., Nickell, K.G., Cline, K., Winkler, H., and Wells, W.G., "Nonsurgical transurethral collagen denaturation for stress urinary incontinence in women: 18-month results from a prospective long-term study," *Neurourol Urodyn* 29, 1424-8 (2010).
- [10] Coad, J.E. and Vos, J.A., "Non-invasive radiofrequency tightening of the vagina in a sheep model," [abstract] *J Sex Med* 7(supp 3), 131 (2010).
- [11] Fitzpatrick, R., Geronemus, R., Goldberg, D., Kaminer, M., Klimer, S., and Ruiz-Esparza, J., "Multicenter study of noninvasive radiofrequency for periorbital tissue tightening," *Lasers Surg Med* 33, 232-242 (2003).
- [12] Wall, M.S., Deng, X.H., Torzilli, P.A., Doty, S.W.B., O'Brien, S.J., and Warren, R.F., "Thermal modification of collagen," *J Shoulder Elbow Surg* 8, 339-44 (1999).
- [13] Sotomayor, M. and Bernal, G.F., "Twelve-month results of nonsurgical radiofrequency energy micro-remodeling for stress incontinence," *Int Urogynecol J Pelvic Floor Dysfunct* 16, 192-6 (2005).
- [14] Dillon, B. and Dmochowski, R., "Radiofrequency for the treatment of stress urinary incontinence in women," *Curr Urol Rep* 10, 369-74 (2009).
- [15] Elser, D.M., Mitchell, G.K., Miklos, J.R., Nickell, K.G., Cline, K., Winkler, H., and Wells, W.G., "Nonsurgical transurethral collagen denaturation for stress urinary incontinence in women: 12-month results from a prospective long-term study," *J Minim Invasive Gynecol* 16, 56-62 (2009).
- [16] Kumar, V., Abbas, A.K., Fausto, N., and Aster, J.C., *Robbins and Cotran Pathologic Basis of Disease*, 8<sup>th</sup> ed., Saunders (imprint of Elsevier Inc.), Philadelphia, PA, Chapter 3 (2010).